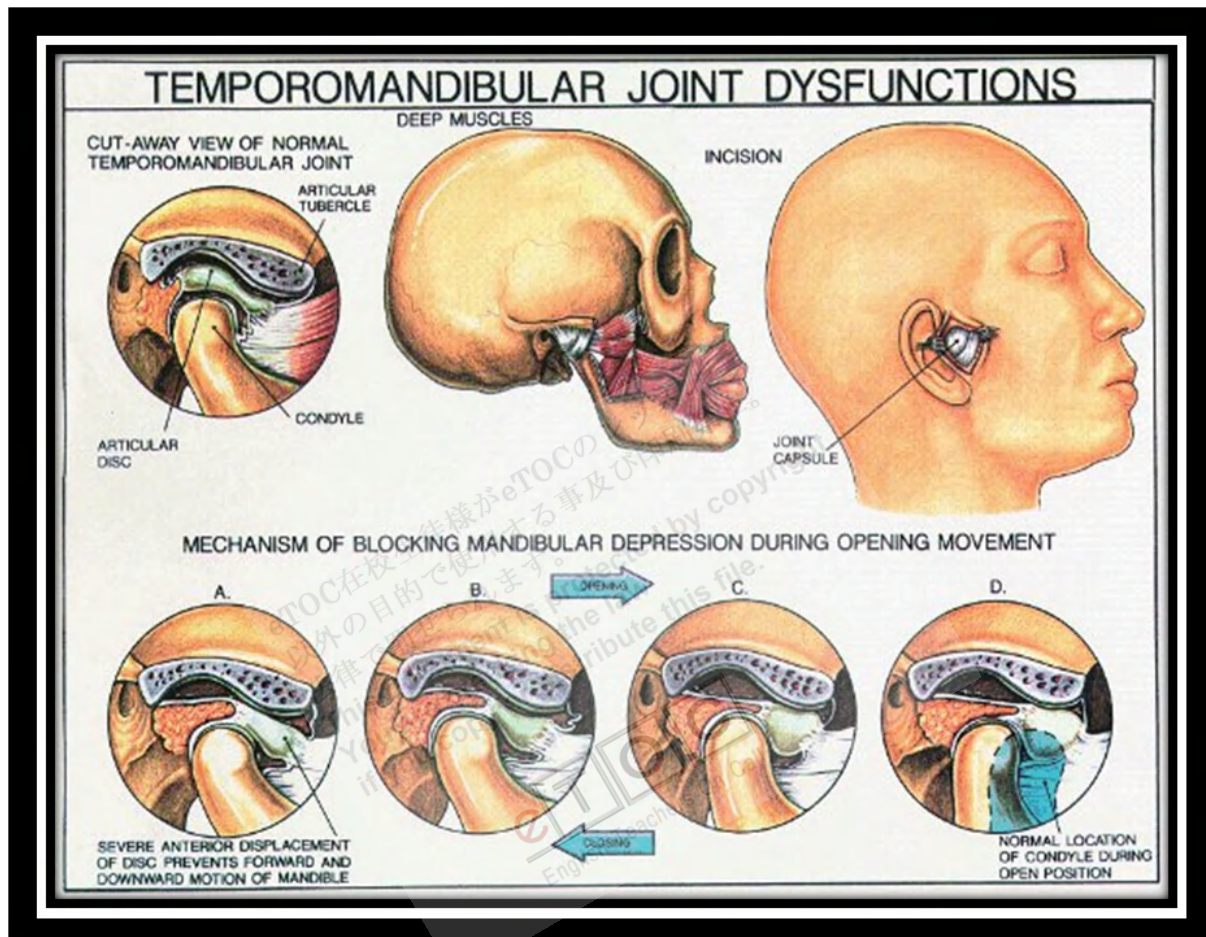


Arthritis of the Temporomandibular Joint (TMJ)



<http://www.intelligentdental.com/wp-content/uploads/2012/01/TMJ.jpg>

Infectious arthritis, traumatic arthritis, osteoarthritis, RA, and secondary degenerative arthritis can affect the TMJ.

Infectious arthritis: Infection of the TMJ may result from direct extension of adjacent infection or **hematogenous** spread of **bloodborne** organisms. The area is inflamed, and jaw movement is limited. Local signs of infection associated with evidence of a systemic disease or with an adjacent infection suggest the diagnosis. X-ray results are negative in the early stages but may show bone destruction later. If **suppurative arthritis** is suspected, the joint is aspirated to confirm the diagnosis and to identify the causative organism. Diagnosis must be made rapidly to prevent permanent joint damage.

Treatment includes antibiotics, proper hydration, pain control, and motion restriction. Parenteral penicillin G is the drug of choice until a specific bacteriologic diagnosis can be made on the basis of culture and sensitivity testing. **Suppurative infections** are aspirated or incised. Once the infection is controlled, jaw-opening exercises help prevent scarring and limitation of motion.

Traumatic arthritis: Rarely, acute injury (eg, due to difficult tooth extraction or **endotracheal intubation**) may lead to arthritis of the TMJ. Pain, tenderness, and limitation of motion occur. Diagnosis is based primarily on history. X-ray results are negative except when **intra-articular edema** or **hemorrhage** widens the joint space. Treatment includes NSAIDs, application of heat, a soft diet, and restriction of jaw movement.

Osteoarthritis: The TMJ may be affected, usually in people > 50 yr. **Occasionally**, patients complain of stiffness, grating, or mild pain. Crepitus results from a hole worn through the disk, causing bone to grate on bone. Joint involvement is generally bilateral. X-rays or CT may show flattening and lipping of the condyle, suggestive of dysfunctional change. Treatment is symptomatic.

Rheumatoid arthritis: The TMJ is affected in > 17% of adults and children with RA, but it is usually among the last joints involved. Pain, swelling, and limited movement are the most common findings. In children, destruction of the condyle results in mandibular growth disturbance and facial deformity. **Ankylosis** may follow. X-rays of the TMJ are usually negative in early stages but later show bone destruction, which may result in an anterior open-bite deformity. The diagnosis is suggested by TMJ inflammation associated with polyarthritis and is confirmed by other findings typical of the disease.

Treatment is similar to that of RA in other joints. In the acute stage, NSAIDs may be given, and jaw function should be restricted. A night guard or splint is often helpful. When symptoms subside, mild jaw exercises help prevent excessive loss of motion. Surgery is necessary if **ankylosis** develops but should not be done until the condition is quiescent.

Secondary degenerative arthritis: This type of arthritis usually develops in people aged 20 to 40 after trauma or in people with persistent **myofascial pain syndrome**. It is characterized by limited opening of the mouth,

unilateral pain during jaw movement, joint tenderness, and crepitus. When it is associated with the [myofascial pain syndrome](#), symptoms wax and wane. Diagnosis is based on x-rays, which generally show [condylar flattening](#), [lipping](#), [spurring](#), or [erosion](#). Unilateral joint involvement helps distinguish secondary degenerative arthritis from osteoarthritis.

Treatment is conservative, as it is for myofascial pain syndrome, although [arthroplasty](#) or high [condylectomy](#) may be necessary. An [occlusal splint](#) (mouth guard) usually relieves symptoms. The splint is worn constantly, except during meals, oral hygiene, and appliance cleaning. When symptoms resolve, the length of time that the splint is worn each day is gradually reduced. [Intra-articular](#) injection of [corticosteroids](#) may relieve symptoms but may harm the joint if repeated often.

eTOC在校生徒様がeTOCのレッスン
以外の目的で使用すること及び印刷禁止。
法律で罰せられます。
This document is protected by copyright.
You are breaking the law
if you copy or distribute this file.

eTOC
English Teachers On Call